

EFFECTIVENESS OF POSITIONAL STRETCHING OF CORACOHUMERAL LIGAMENT IN ADDITION TO ULTRASOUND IN PATIENT WITH ADHESIVE CAPSULITIS

Bikash Shrestha,¹ Manisha Munikar²

¹Physiotherapy, Nepal Police Hospital

²Physiotherapy, Nepal Trauma Center

ABSTRACT

Introduction: Adhesive capsulitis is an idiopathic condition of the shoulder characterized by onset of pain and movement restriction and symptoms can last up to 2 years and longer. The primary goal of intervention is to improve ROM, pain and decrease disability. The objective of the study is to determine the combined effect of positional stretching of coracohumeral ligament and ultrasound therapy in patient with adhesive capsulitis.

Methods: 30 subjects were included in the study. Each subject was assigned into two groups. One group was treated with ultrasound followed by positional coracohumeral ligament stretching and another group was treated with ultrasound only. The duration of treatment was 3 to 4 weeks (10- 12 sessions) in both groups. Primary outcome measure included ROM and SPADI.

Results: Both groups showed significant improvement but in comparison of two groups, group A (ultrasound followed by positional CHL stretching) was more effective than group B (ultrasound only).

Conclusions: Addition of Positional coracohumeral ligament stretching and ultrasound is effective than ultrasound only in decreasing pain and improving ROM in Adhesive capsulitis.

Keywords: Adhesive capsulitis; Coracohumeral ligament; Positional stretching; ultrasound.

INTRODUCTION

Shoulder is a complex anatomic structure that allows movement in many planes.¹ Shoulder pain is a common problem, it is the third most common musculoskeletal complaint in the general population and accounts for 5% of all general practitioner musculoskeletal consultation.²

With the given evidence it is known that ultrasound helps in collagen tissue

extensibility and CHL stretching helps in increasing ROM. But it is not known if ultrasound is added prior to CHL, whether it will help in increasing further ROM. And in the study done by Indhuja et al (unpublished),³ comparison between positional CHL stretching and ultrasound was done. So, the need arises whether the addition of ultrasound with positional CHL stretching is effective in increasing further ROM.

To determine the combined effect of positional stretching of coracohumeral ligament and ultrasound therapy in patient with adhesive capsulitis.

Correspondance:

Bikash Shrestha,

Nepal Police Hospital, Physiotherapy.

Email: viku.stha5031@gmail.com

Phone: 9860280258

METHODS

This pre-post experimental study involved collection of data from Padmashree Clinic of Physiotherapy, Nagarbhavi, Bangalore, ESI hospital, Rajaji Nagar, Bangalore and Ravi Kirloskar Memorial Hospital, Peenya 3rd stage, Bangalore for the period of six months. The study population include subjects with freezing stage of adhesive capsulitis. Sample of 30 was taken by convenience sampling from the population fulfilling the inclusion criteria. A written consent form was obtained from all the subjects. 30 subjects were divided into two groups each consisting 15. Pre-treatment examination was done to assess pain and range of motion with the help of SPADI and Goniometer

Inclusion criteria:

- Patients with primary adhesive capsulitis.
- Restriction of external rotation, abduction of the glenohumeral joint when compared to the opposite side.
- Age: 41-60 years
- Both genders were taken.
- Patients presenting with symptoms preceeding 3 months and not exceeding 9 months.

Exclusion criteria:

- Uncontrolled diabetes.
- Unstable joint.
- Hemiplegic Shoulder joint.
- Concurrent cervical signs and symptoms.
- History of fracture and dislocation of the shoulder.
- Post surgical cases around shoulder.
- Musculoskeletal conditions affecting the shoulder such as Bicipital tendonitis, Supraspinatus tendonitis, Painful arc syndrome, Post traumatic shoulder stiffness etc
- Thoracic outlet syndrome.
- Cases of diagnosed bone infections.

- Malignancies.
- Cortico steroid injection Preceding 3 months.

Parameters: Assessment was conducted on first day and last day of treatment session by using the following parameters.

- Goniometer
- Shoulder Pain and Disability Index (SPADI)

Group A

15 subjects were treated with ultrasound in pulsed mode (1:4) with an intensity of 1.0w/cm² for duration of 10 minutes for 3 to 4 weeks.³³ Followed by positional stretching of coracohumeral ligament in patient with adhesive capsulitis.

Procedure of positional stretching of coracohumeral ligament

First the patient was taught the procedure of stretching and was made to lie down comfortably.

Each of the 15 patients was sidelying on the unaffected side with pillow placed under the patient's head to keep the head aligned with the body. The affected arm was resting on the patient's side. Patient was instructed to grab a 20–22 inch dowel with the affected arm, always keeping the left forearm supinated in order to encourage shoulder external rotation. Patient was explained that forearm pronation would lead the shoulder into internal rotation and the CHL into a slack position, a loose, relaxed, and inefficient position for stretching the CHL. With one end of the dowel on the table, Patient was instructed to hyperextend the shoulder approximately 10° and then adduct the arm as close to the body as tolerated by sliding the hand down the dowel.

Then the patient was told to expect a slight stretch sensation in the anterolateral aspect of the shoulder and possibly in the region of the bicipital tendon further distally and was asked to maintain the stretch for 30 seconds.

With the help of a dowel patient can 1) gradually slide the hand down into extension and adduction, 2) keep the forearm supinated, and 3) avoid fatigue of the arm just hanging behind the body.

Patient was asked to do 3 sets of 10 repetitions in a day. Rest periods of 30 seconds were given in between.

Group B

Each of the 15 subjects was treated with ultrasound in pulsed mode (1:4) with an intensity of 1.0w/cm² for duration of 10 minutes for 3 to 4 weeks.³²

Data analysis was performed by SPSS (version 17) for windows. Alpha value was set as 0.05.

Descriptive statistics was used to find out mean, standard deviation and range for demographic and outcome variable.

For pain, Wilcoxon's test was used to compare within the groups and Mann-Whitney U-test was used to compare between the groups.

For ROM, paired t-test was used to compare within the groups and Unpaired t-test was used to compare between the groups.

Microsoft word and Excel have been used to generate graphs, tables etc.

RESULTS

A study with 30 adhesive capsulitis was randomized into 15 subjects as experimental group and 15 subjects as control group. Experimental group received ultrasound followed by positional coracohumeral ligament stretching and control group received ultrasound only. The effect of the study was evaluated based on ROM and SPADI.

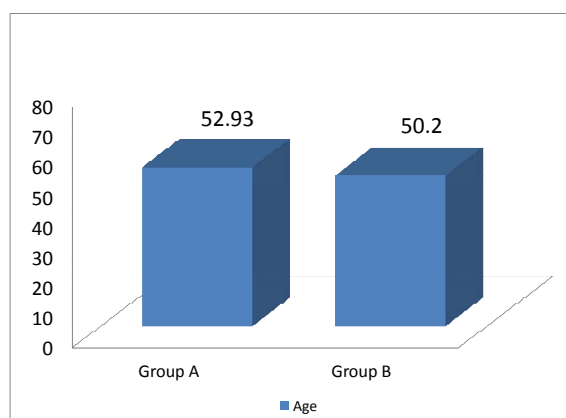
Table 1. Baseline data for demographic variable.

S.N:	Variable	Group A	Group B	P-value
1	Age	52.93±5.44	50.20±4.39	>0.141
2	Gender (M/F)	10/5	9/6	>0.705

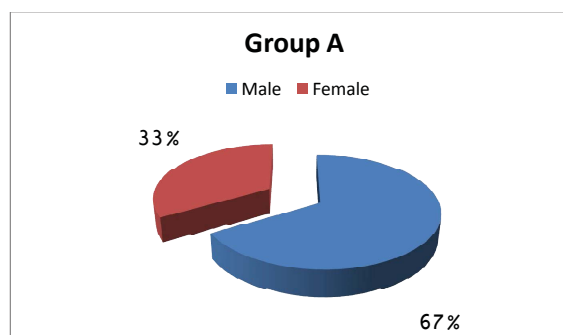
Data are Mean ± Standard Deviation. Tables 1 represent:

In experimental group Mean Age was 52.93 with Standard Deviation of 5.44. In control group, the Mean Age was 50.20 with standard deviation of 4.39 which was statistically not significant. (P>0.141)

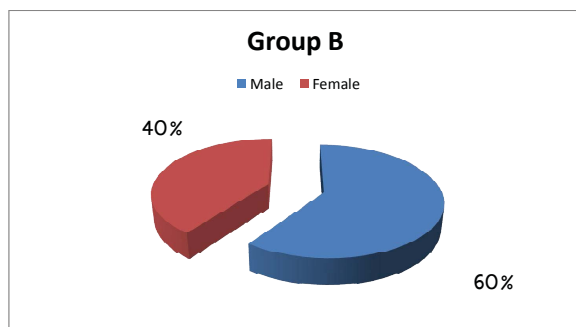
In experimental group, there were 10 males and 5 females. And in control group, there were 9 males and 6 females.



Graph 1. Baseline data for demographic variable- Age.



Graph 2. Baseline data for demographic variable – Gender.



Graph 3. Baseline data for demographic variable- Gender.

Table 2. Baseline data for outcome variable.

S.N:	Variable	Group A	Group B	P-value
1	Flexion	114.33±19.54	111.00±14.42	>0.599
2	Abduction	91.20±20.22	85.67±11.78	>0.368
3	External rotation	29.33±9.23	26.87±7.47	>0.428
4	Internal rotation	28.33±5.88	26±10.04	>0.444
5	SPADI	87.18±5.74	85.84±4.16	>0.512

Data are Mean ± Standard Deviation. Table 2 Represent:

In experimental group, mean flexion was 114.33 with standard deviation of 19.54. In control group, the mean flexion was 111.00 with standard deviation of 14.72 which was statistically not significant ($p>0.599$)

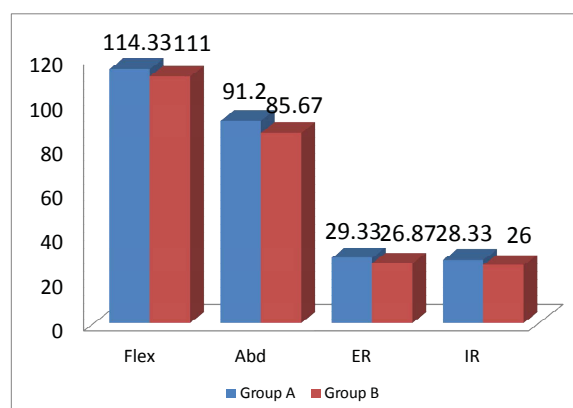
In experimental group, mean abduction was 91.20 with standard deviation of 20.22. In control group, the mean abduction was 85.67 with standard deviation of 11.78 which was statistically not significant ($p>0.368$)

In experimental group, mean external rotation was 29.33 with standard deviation of 9.23. In control group, the mean flexion was 26.87 with standard deviation of 7.47 which was statistically not significant ($p>0.428$)

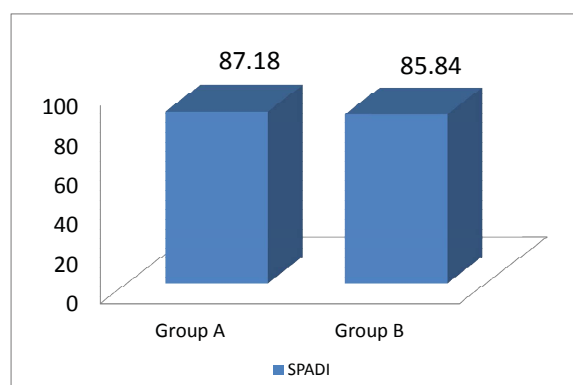
In experimental group, the mean internal rotation was 28.33 with standard deviation of 5.88. In control group the mean internal rotation was 26 with standard deviation of

10.04 which was statistically not significant ($p>0.444$)

In experimental group, the mean SPADI was 87.18 with standard deviation of 5.74. In control group, the mean SPADI was 85.84 with standard deviation of 4.16 which was statistically not significant ($p>0.512$).



Graph 4. Baseline data for outcome variable - ROM.



Graph 5. Baseline data for outcome variable- SPADI.

Table 3. Within experimental group.

S.N:	Variable	Pre	Post	P-value
1	Flexion	114.33±19.54	144.40±20.12	<0.0001
2	Abduction	91.20±20.22	122.00±25.41	<0.0001
3	External rotation	29.33±9.23	52.53±12.47	<0.0001
4	Internal rotation	28.33±5.88	53.93±8.58	<0.0001
5	SPADI	87.18±5.74	40.72±5.95	<0.001

Data are Mean \pm Standard Deviation. Table 3 represents:

In experimental group, mean flexion was 114.33 with standard deviation of 12.46 increased to 144.40 with standard deviation of 20.12 which was statistically significant ($p < 0.0001$)

In experimental group, mean abduction was 91.20 with standard deviation of 20.22 increased to 122.00 with standard deviation of 25.41 which was statistically significant. ($p < 0.0001$)

In experimental group, mean external rotation was 29.33 with standard deviation of 9.23 increased to 52.53 with standard deviation of 12.47 which was statistically significant ($p < 0.0001$)

In experimental group, mean internal rotation was 28.33 with standard deviation of 5.88 increased to 53.93 with standard deviation of 8.58 which was statistically significant ($p < 0.0001$)

In experimental group, mean SPADI was 87.18 with standard deviation of 5.74 increased to 40.72 with standard deviation of 5.95 which was statistically significant. ($p < 0.001$)

DISCUSSION

This study was aimed to find out the effect of positional coracohumeral ligament stretching with ultrasound in Adhesive capsulitis shoulder and to compare with ultrasound. Based on the finding of this study, it was found there was an additive effect of positional coracohumeral ligament stretching with ultrasound than giving ultrasound alone.

In this study, total 30 subjects were taken.¹⁵ in each group 18 male and 12 female which was homogenous. Baseline demographic variables were taken which includes age and gender.

In this study outcome measure taken was SPADI (Shoulder Pain And Disability Index) for Pain and Goniometer for shoulder ROM.

According to Simon Carrette et al³⁴, SPADI is a self-administered instrument that measures pain and disability associated with shoulder disease. It consists of 13 items divided into 2 subscales: pain (5 items) and disability (8 items). SPADI including both the pain and the disability scales have been shown to have high levels of internal consistency (Cronbach's α 0.86–0.95) and correlates negatively with shoulder range of motion. It was found to have moderate test-retest reliability for measuring pain and functional outcome. The author suggested that the instrument is sensitive to clinical changes and accurately discriminates between patients with shoulder disease who have improved those whose condition has remained unchanged, and those who have worsened.

Within the group analysis of group A, ultrasound and positional CHL stretching was found to be statistically significant in improving pain and ROM. This was in accordance with study done by Jose Orlando Ruiz et al 'Positional Stretching of the Coracohumeral Ligament on a Patient with Adhesive Capsulitis' found out gain in passive external rotation and in active shoulder abduction after applying positional stretching technique for four weeks however, this was a case study. According to his study changes in ROM due to viscoelastic phenomena can be demonstrated by procedures that are typically applied for brief periods such as joint mobilization and other passive techniques which are not effective in increasing ROM. So, the involved tissue needs to be stretched along the lines of stress to produce re-alignment of tissue. And author had suggested that there is a direct correlation between the duration of a stretch and the resulting proportion of permanent elongation, longer the duration of stretching helps for plastic response. And author had used positional coracohumeral ligament stretching to increase ROM which was proven to be effective.⁴

Philip W McClure and Kenneth R Flowers suggested that the limited motion attributable to adaptive shortening of periarticular tissues is most effectively treated by methods

that hold the joint at or near the end range of motion for prolonged periods of time. According to the author the limited ROM is thought to be due to a structural change in the periarticular tissues, and the structures could potentially limit the ROM. So, the stretching technique should be selected based on the type of maneuver which best puts tension on the restricting tissue. The therapist should consider the structures which could potentially limit the ROM when limited ROM is thought to be due to a structural change in the periarticular tissues. Treatment of limited PROM attributed to structural changes that geared towards applying tension to cause elongation of the restricting tissues. This contrast to treatment of limited ROM attributed to nonstructural changes focused on relieving the problem producing the limitation in ROM.⁵

In the study done by Indhuja et al (unpublished) "Effect of positional coracohumeral ligament stretching in patients with adhesive capsulitis: A randomized controlled trial" found positional CHL stretching to be effective in increasing ROM. According to her study, it was hypothesized that based on viscoelastic phenomenon improvement in ROM may be due to increased extensibility of non contractile tissues after stretching.³

According to Andrea J. Johnson et al, ultrasound helps to alter the viscoelastic properties of the connective tissue and maximize the effectiveness of the stretch. Author reported that ultrasound provide the target tissue with a moderate to vigorous temperature rise of 3°C to 4°C, which is deemed adequate to alter the viscoelastic properties of connective tissue.⁶

Within the group analysis of group B, Ultrasound was found to be statistically significant

in reducing the pain. The results of this study demonstrated that at the end of the intervention period, the subjects with adhesive capsulitis of shoulder showed improvements in pain, ROM. In accordance

to Robert A Donatelli et al, the physiologic response due to ultrasound therapy includes increased collagen tissue extensibility, pain threshold and enzymatic activity, along with changes in nerve conduction velocity, contractile activity of skeletal muscle.⁷

According to Leonie E. Warmington, ultrasound had a much greater depth of penetration than other forms of heat which could be localized much more accurately. It is one of the mechanical properties of ultrasound which is superior than other forms of heat modalities due to which ultrasound is much more likely to affect the joint capsule lessening the inflammatory process.⁸

According to Reed B et al, ultrasound increases collagen tissue extensibility, and its effect of heating performed on human knees with clinically accepted doses (1.5 W/cm² at 1 MHz for 8 minutes) slightly increased the extensibility of the lateral and medial collateral ligaments, but this increase was not significant.⁹ Studies by other researchers; Mao CY et al,¹⁰ Ebenbichler GR et al,¹¹ Akgun K et al,¹² supports the efficacy of US therapy in improving pain, activities of daily living, and quality of life.

According to Hacer Dogru et al, therapeutic ultrasound and sham ultrasound had no significant difference in pain, SPADI and SF-36 scores between groups. And their results suggested that US compared with sham US gave no relevant benefit in the treatment of adhesive capsulitis.¹³ According to van der Windt et al, a systematic review on Ultrasound therapy for musculoskeletal disorders was evaluated to find the effectiveness of ultrasound therapy in the treatment of musculoskeletal disorders. The authors found that there was little evidence to support the use of ultrasound therapy in the treatment of musculoskeletal disorders. In the study, their literature did not support the existence of clinically important or statistically significant differences in favour of ultrasound therapy. The authors concluded that US is not effective in placebo-controlled trials when compared with sham ultrasound.¹⁴

CONCLUSIONS

It can be assumed that addition of positional coracohumeral ligament stretching with ultrasound was effective. As there was statistically difference between the two groups, the experimental hypothesis was accepted and the null hypothesis was rejected. The study could be concluded as: "There was an additive effect of positional coracohumeral ligament stretching with ultrasound in patient with adhesive capsulitis."

The following recommendations can be made:

- May be done in stage III adhesive capsulitis patients who can help to know the duration of recovery time.
- May be done in large sample size
- May be done in diabetes patients in future to find out the treatment duration

CONFLICT OF INTEREST: None.

REFERENCES

1. Lori B. Siegel, Norman J. Cohen et al. Adhesive Capsulitis: A sticky Issue. American Academy of Family Physicians. 1999 April 1.
2. J. Herbert Stevenson and Thomas Trojian. Evaluation of shoulder pain. The Journal of Family Practice. July 2002; 51(7)
3. Indhuja et al. The effect of positional coracohumeral ligament stretching in patients with adhesive capsulitis: A randomized controlled trial". (unpublished); 1-60
4. Jose Orlando Ruiz. Positional Stretching of the Coracohumeral Ligament on a patient with Adhesive Capsulitis Patients: A case report. Journal of Manual and Manipulative Therapy 2009; 17(1): 58-63.
5. Philip W McClure Kenneth R Flowers. Treatment of Limited Shoulder Motion: A Case Study- Based on Biomechanical Considerations. Journal of American Physical Therapy Association. 1992; 72: 929-936.
6. Andrea J. Johnson, Joseph J. Godges, Grenith J. Zimmerman, Leroy L. Ounanian. The Effect of Anterior Versus Posterior Glide Joint Mobilization on External Rotation Range of Motion in Patients With Shoulder Adhesive Capsulitis journal of orthopaedic & sports physical therapy 2007; 37(3): 88-99.
7. Robert A Donatelli, Micheal J and Wooden, Orthopaedic Physical therapy. 3rd ed Churchill Living Stone publication; 153-158.
8. Leonie E. Warmington. A frozen shoulder: An effective method of treatment. Australian journal of physiotherapy 1970; 3: 124-130
9. Reed B, Ashikaga T. The effects of heating with ultrasound on knee joint displacement. J Orthop Sports Phys Ther. 1997; 26: 131-137.
10. Mao CY, Jaw WC, Cheng HC. Frozen shoulder: correlation between the response to physical therapy and follow-up shoulder arthrography. Arch Phys Med Rehabil. 1997; 78: 857-859.
11. Ebenbichler GR, Erdogmus, CB, Resch KL, et al. Ultrasound therapy for calcific tendinitis of the shoulder. N Engl J Med. 1990; 340: 1533-1538.
12. Akgun K, Tuzun, F, Akarirmak U, et al. Efficacy of ultrasonic diathermy in conservative treatment of impingement syndrome. Rheumatology Europe. 1995; 24(suppl 3): 198.
13. Hacer Dogru, Sibel Basaran, Tunay Sarpel. Effectiveness of therapeutic ultrasound in adhesive capsulitis Joint Bone Spine 2008; 75(4): 445-450
14. Van der Windt, van der Heijden, van der Berg, et al. Ultrasound therapy for musculoskeletal disorders: a systematic review. Pain. 1999; 81: 257-271.