

Guide Flange Prosthesis with Acrylic Guidance Ramp for Management of Deviation following Segmental Mandibulectomy and Partial Maxillectomy for Gingivobuccal Mucosal Cancer

Anjali Tandukar¹, Bodh Bikram Karki², Saroj Singh², Pramod Raj Joshi¹

¹Department of Prosthodontics and Maxillofacial Prosthetics, Nepal Police Hospital, Kathmandu, Nepal

²Department of Oral and Maxillofacial Surgery, Nepal Police Hospital, Kathmandu, Nepal

ARTICLE HISTORY

Received : 23 Oct 2021

Accepted: 08 Nov 2021

ACCESS THE ARTICLE ONLINE



DOI: <https://doi.org/10.37080/nmj.182>

ISSN : 2645-8438

KEYWORDS

Guide flange prosthesis; oral cancers; partial maxillectomy; segmental mandibulectomy; mandibular deviation

DISCLAIMER:

This report has never been presented anywhere.

CORRESPONDENCE:

Anjali Tandukar

Department of Prosthodontics and Maxillofacial Prosthetics, Nepal Police Hospital, Kathmandu
E-mail: anjalitandukar@gmail.com

CONFLICT OF INTEREST : None

Copyright: The Author(s) 2021. This is an open access article under the CC BY license.



ABSTRACT

Surgical resection of maxilla and /or mandible due to presence of benign or malignant tumor is most common. Segmental resection frequently causes deviation of mandible towards the defective side and disturbances in maxillomandibular relationship. Variety of materials and techniques have been used for the construction of prosthetic replacement of acquired surgical defects. This case report describes prosthodontic management of a patient who has undergone partial maxillectomy and segmental mandibulectomy using the mandibular guide flange prosthesis with acrylic guidance ramp. This not only helps to correct the deviation but also guide the mandible for achieving occlusal contact with opposing teeth.

INTRODUCTION

Gingivobuccal mucosa cancers (GBCs) are the most common oral cavity cancers. Depending upon the location and content of the tumor in maxilla and mandible, various surgical treatment modalities like partial/total maxillectomy, marginal, segmental, hemi, subtotal or total mandibulectomy can be performed. Segmental resection frequently results in deviation of mandible towards the defective side and disturbances in maxillomandibular relationship.¹ Apart from deviation, other dysfunctions such as difficulty in mastication, swallowing, speech, mandibular movement, respiration, esthetics and psychic functioning can occur.² The quantity of deviation depends upon the amount of hard and soft tissue involvement, method of surgical site closure, degree of impaired tongue function, number of remaining teeth and innervation involvement.^{3,4} The management for such patients are surgical re-establishment of resected part, physiotherapy and prosthodontic intervention and rehabilitation. Various design of prosthesis either mandibular based or palatal based, anchored on natural teeth or the denture flange or implant supported prosthesis have been employed to minimize deviation and improve masticatory efficiency.³⁻⁵ This case report describes the prosthodontic rehabilitation of a patient with partial maxillectomy and segmental mandibulectomy using a mandibular guide flange

How to cite (Vancouver Style)

Tandukar A, Karki BB, Singh S, Joshi PR. Guide Flange Prosthesis with Acrylic Guidance Ramp for Management of Deviation following Segmental Mandibulectomy and Partial Maxillectomy for Gingivobuccal Mucosal Cancer: A Case Report. Nepal Med Jor [Internet]. [cited 2021 Aug.23];4(1). Available from: <https://www.nmj.com.np/nmj/index.php/nmj/article/view/182>

prosthesis with acrylic guidance ramp (GFP).

CASE REPORT

A 34-year-old male patient diagnosed with left gingivobuccal mucosal cancers (GBCs) of both maxilla and mandible was treated by oral surgery team of Nepal Police Hospital. The patient had undergone partial maxillectomy and segmental mandibulectomy followed by reconstruction with anterolateral thigh free flap. After one-month follow-up, patient complained of deviation of mandible to the left side while opening and closing his mouth and inability to bite properly following the surgery (about 7-9 mm from midline on 28 mm of mouth opening). Patient's habits revealed that he was betel quid chewer and had bilateral oral submucous fibrosis. A removable intermediate mandibular acrylic guide flange was planned as an early treatment option for the patient.

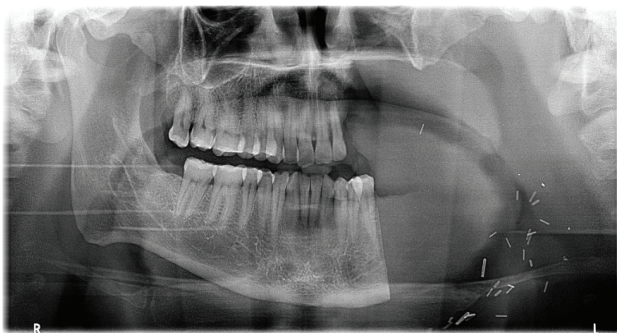


FIG. 1: Post-surgical panoramic radiograph

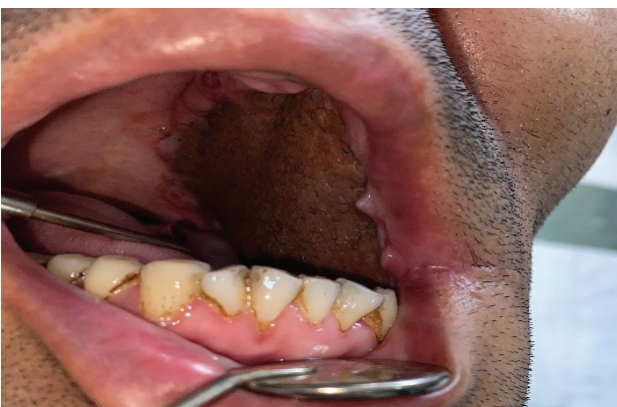

FIG. 2: Intral oral view showing free flap. Note the deviation of mandible to defect (left) side on opening

An orthopantomogram revealed resection of the maxilla distal to left canine and resection of mandible distal to left second premolar

involving ramus, coronoid process and condyle (Fig- 1, Cantor and Curtis Class II). On extraoral examination, there was facial asymmetry and deviation of mandible to the left side that is surgical side (Fig- 2). There was limited mouth opening due to post-surgical scarring and fibrosis of buccal mucosa of right side. Intraoral examination revealed missing teeth in left side of maxilla and mandible. The patient was able to achieve normal medio-lateral position of the mandible and repeat this position consistently for adequate mastication. No immediate treatment such as intermaxillary fixation and/or physiotherapy program was provided to the patient.

PROCEDURE

A stainless steel stock edentulous tray (modified by trimming buccal flange of left half) was taken and impression of maxillary and mandibular arch was made with irreversible hydrocolloid (Zelgan Densply Alginate, India). The impressions were poured in Type IV gypsum materials (Kalabhai Kalrock Die stone, India). Casts were mounted on the mean value articulator. The retention was provided by the interdental clasp engaging the premolar and molars (Fig-3). The guidanceramp and mandibular guide flange was waxed up with modelling wax around wire substructure by keeping a maxillary cast in occlusion and subsequently acrylised with heat polymerized acrylic resin (DPI Heat Cure Acrylic, Mumbai, India).

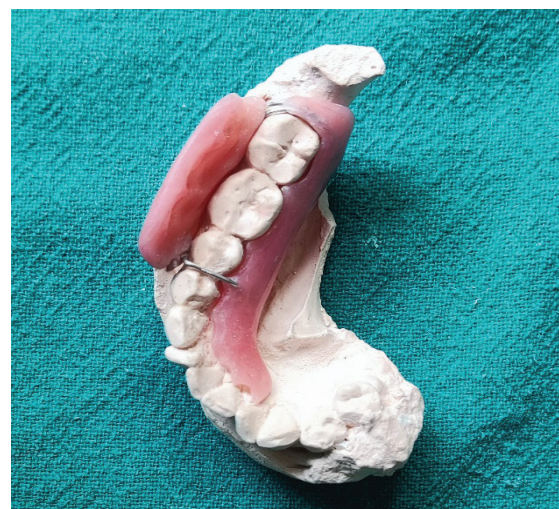


FIG. 3 Wire substructure: occlusal view



FIG. 4 Completed guiding flange prosthesis. Note arrows indicating the buccal indentation of opposing maxillary teeth

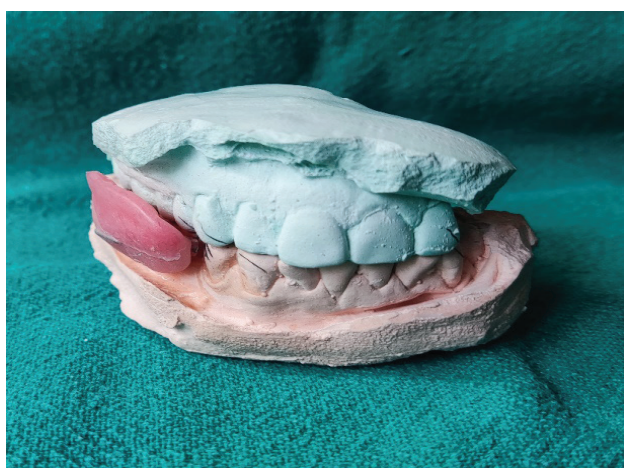

FIG. 5: Buccal extension of acrylic guidance ramp.

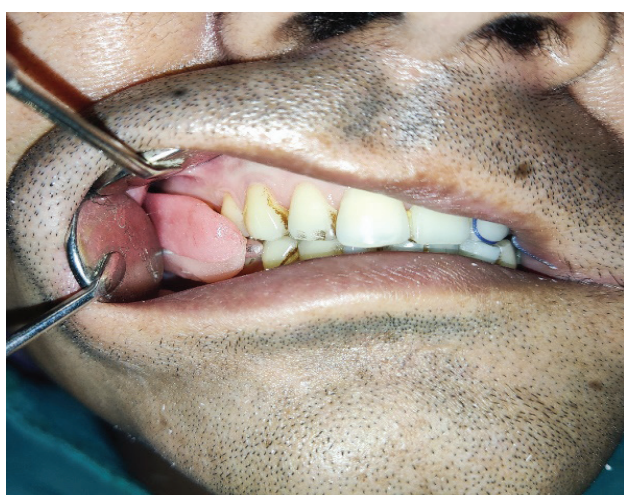

FIG. 6 Final prosthesis: intraoral view. Note the correction of the deviation.

The inclination of the acrylic ramp was adjusted by selectively trimming the teeth contacting surface or adding the autopolymerizing acrylic resin (DPI cold cure) on chairside. Thus acrylic ramp was developed intraorally to guide the mandible in definite position. Care was taken to preserve the buccal surface indentation of opposing maxillary teeth which were guiding the mandible in a final definitive closing point during mastication (Fig- 4). The flange height was adjusted in such a way that it guided the mandible from large opening position (in practical limits of the height of the buccal vestibule) to maximum intercuspation in a smooth and unhindered path (Fig-5).

The prosthesis was delivered and patient was trained to close the mandible in desired position (Fig-6) The patient was followed up after 24 hours, 1 week and 1 month. No adjustment was required till last follow up. On further visits, with the improvement of deviation of mandible, the angulation of ramp may be adjusted by adding acrylic to medial surface of ramp.⁶ Till last follow-up, patient was content with treatment as he was able to achieve a functional intercuspation and chew food properly. The deviation was reduced to some extent.

DISCUSSION:

Depending on the location and extent of the tumor in maxilla /mandible, various surgical correction modalities such as partial/total maxillectomy and marginal, hemi, subtotal or total mandibulectomy are performed. Loss of mandibular continuity causes deviation of remaining mandibular segments towards the defect and rotation of mandibular plane inferiorly. This mandibular shift is due to the uncompensated influence of the contra lateral musculature particularly the medial pterygoid muscle. If the influence is left uncompensated, the contraction of the cicatricial tissue on the operated side will fix the residual fragment in its deviated position. This situation leads to facial deformity and function loss.⁷

Sahin et al.⁸ and Chalian et al.⁹ stated the fabrication of a cast metal guidance prosthesis with supporting and retentive flanges. They claimed that the patient was able to achieve a functional intercuspation position with the help of the prosthesis but that mastication was

limited to vertical movement only. Joshi et al. described the fabrication of a removable type of mandibular guide flange prosthesis as an alternative for most patients with mandibular defects, considering the poor prognosis and economic feasibility.¹⁰ Nelogi et al described the fabrication of a fixed guide flange appliance that consisted of a molar band with a U-loop cemented to the teeth and claimed especially helpful for patients with reduced mouth opening and poor motor skills.¹¹ Principe et al described the fabrication of a mandibular guiding flange attached to the removable partial denture by two precision attachments.¹²

With the advancement in facial reconstruction surgery and dental implants, it is easier to provide a treatment modality that adequately rehabilitates oral cancer patients so that they can live a much better life. For replacing the missing teeth for reconstructed mandibulectomy patients, the clinicians must wait for extensive period of time (more than a year) for completion of healing and acceptance of the osseocutaneous/fasciocutaneous flap. During this initial healing period early prosthodontic intervention by mandibular guide flange prosthesis with guidance ramp serve the purpose of reducing mandibular deviation and improving the masticatory efficiency. This GFP can be regarded as an intermediate prosthesis. Financial constraints of the patients limited our treatment options and precluded the selection of cast partial framework, so a simple, economic acrylic guide flange prosthesis with guidance ramp was planned for this patient.

Support for the GFP is no different from that of any other removable prosthesis, the natural teeth and the residual alveolar ridge being the primary sources. Multiple retentive clasps in widely distributed areas of the arch would be the best approach, but actual placement would be determined by the position of the teeth. Retentive elements should be no more rigid than necessary, but they require a more rigidity with a decreasing number of teeth.¹³ The lingual extension of guide flange extends to the entire lingual sulcus of remaining teeth of mandible to improve the stability of the prosthesis. Care must be taken not to extend the prosthesis in the junctional area of the graft and the normal tissue.

Mandibular guidance therapy is more successful in patients whose resection involves only bony structure with minimal loss of soft tissue, no radical neck dissection or radiation therapy.¹⁴ The GFP can be regarded as a training type of prosthesis. If the patient can successfully repeat the mediolateral position, the GFP can often be discontinued. Some patient, however, may continue indefinitely with a guide flange, and the stress generated to the remaining teeth must then be carefully monitored. To prevent tipping of maxillary teeth, maxillary stabilization prosthesis should be considered. GFP is more effective if there is maximum number of teeth in maxillary and mandibular arch. This prosthesis mostly allows for vertical strokes but limited lateral movement.^{8,9}

The GFP can be regarded as a training type of prosthesis. If the patient can successfully repeat the mediolateral position, the GFP can often be discontinued. Some patient, however, may continue indefinitely with a guide flange, and the stress generated to the remaining teeth must then be carefully monitored.

CONCLUSIONS

The guide flange prosthesis with acrylic guidance ramp helps in correcting mandibular deviation to some extent. It improves the functional intercuspation and thus the mastication. Hence, such interim training device aids in guiding the mandible to maximum occlusal contacts thereby improving the quality of the life.

REFERENCES:

1. Beumer J, Curtis T, Marunick M. Maxillofacial rehabilitation: prosthodontic and surgical considerations. St Louis: Ishiyaku EuroAmerica, Inc.; 1996:184-188. In: [\[DOI\]](#) [\[PubMed\]](#) [\[Full Text\]](#)
2. Swoope CC. Prosthetic management of resected edentulous mandibles. *J Prosthet Dent.* 1969 Feb;21(2):197-202. [\[DOI\]](#) [\[PubMed\]](#) [\[Full Text\]](#)
3. Aramany MA, Myers EN. Intermaxillary fixation following mandibular resection. *J Prosthet Dent.* 1977 Apr;37(4):437-44. [\[DOI\]](#) [\[PubMed\]](#) [\[Full Text\]](#)
4. Schneider RL, Taylor TD. Mandibular resection guidance prostheses: A literature review.

- J Prosthet Dent. 1986 Jan;55(1):84-6.[\[DOI\]](#) [\[PubMed\]](#) [\[Full Text\]](#)
5. Ohtake K, Nakajima T. A simple appliance for controlling mandibular movement following segmental resection. J Oral Maxillofac Surg. 1993 Sep;51(9):1048-9.[\[DOI\]](#) [\[PubMed\]](#) [\[Full Text\]](#)
 6. Geramipanah F, Fallahi Sichani S, Mirmohammadrezaei S, Ghodsi S. Practical guidelines for fabricating mandibular guide flange prostheses: A new technique for measuring the flange angulation. Prosthet Orthot Int. 2016 Aug;40(4):528-31. [\[PubMed\]](#) [\[DOI\]](#)
 7. Robinson JE, Rubright WC. Use of a guide plane for maintaining the residual fragment in partial or hemi-mandibulectomy. J Prosthet Dent. 1964 Sep;14(5):992-9.[\[DOI\]](#) [\[PubMed\]](#) [\[Full Text\]](#)
 8. Şahin N, Hekimoğlu C, Aslan Y. The fabrication of cast metal guidance flange prostheses for a patient with segmental mandibulectomy: A clinical report. J Prosthet Dent. 2005 Mar;93(3):217-20.[\[DOI\]](#) [\[PubMed\]](#) [\[Full Text\]](#)
 9. Varoujan A, Chalian S, Miles Standish, Joe B, Drane. Maxillofacial Prosthetics: Multidisciplinary Practice Hardcover - January 1, 1972. In p. 148.
 10. Joshi P, Saini G, Shetty P, Bhat S. Prosthetic rehabilitation following segmental mandibulectomy. J Indian Prosthodont Soc. 2008;8(2):108.[\[DOI\]](#) [\[PubMed\]](#) [\[Full Text\]](#)
 11. Nelogi S, Chowdhary R, Ambi M, Kothari P. A fixed guide flange appliance for patients after a hemimandibulectomy. J Prosthet Dent. 2013 Nov;110(5):429-32.[\[DOI\]](#) [\[PubMed\]](#) [\[Full Text\]](#)
 12. Prencipe MA, Durval E, De Salvador A, Tatini C, Roberto B. Removable Partial Prosthesis (RPP) with acrylic resin flange for the mandibular guidance therapy. J Maxillofac Oral Surg. 2009 Mar;8(1):19-21.[\[DOI\]](#) [\[PubMed\]](#) [\[Full Text\]](#)
 13. Desjardins RP. Relating examination findings to treatment procedures. In: Laney WR. Maxillofacial Prosthetics. Littleton. PSG Publishing; 1979. p. 69-114. In.
 14. Hazra R, Srivastava A, Kumar D. Mandibular guidance prosthesis: Conventional and innovative approach: A case series. J Indian Prosthodont Soc. 2021;21(2):208.